

UDK 616.97#616.853.9"177"

*T. Stetsenko<sup>1</sup>, O. Savchenko<sup>2</sup>, N. Salan<sup>2</sup>, I. Holovatyuk<sup>2</sup>*

## Huntington's chorea in a child. The first description of the disease in Ukraine. Proper observation

<sup>1</sup>Shupyk National Medical Academy of Postgraduate Education, Kyiv, Ukraine<sup>2</sup>National Children's Specialized Hospital «OKHMATDYT», Kyiv, Ukraine

Modern pediatrics. Ukraine. 2019.4(100):60-65; doi 10.15574/SP.2019.100.60

**For citation:** Stetsenko T, Savchenko O, Salan N, Holovatyuk I. (2019). Huntington's chorea in a child. The first description of the disease in Ukraine. Proper observation. Modern pediatrics. Ukraine. 4(100): 60-65. doi 10.15574/SP.2019.100.60

Huntington's disease (HD, ICD-10 — G-10, ICD-11 — 8A01.10) — is an autosomal dominant neurodegenerative disease characterized by motor disorders (chorea in adults and akinetic-rigid syndrome in children), mental disorders and dementia with progressive course and mortality of 100%.

**Aim** of research. To present a unique case of Huntington's chorea diagnosed in a child at the age of 4 in the third generation in the family. This case is described for the first time in Ukraine.

**Results** of research. Girl at the age of 4 years and 7 months who has been admitted to the NCSH «OKHMATDYT» with complaints about linguistic and psychic skills loss, ambulation disorder, and periodic falls from her standing height, episodes of urinary incontinence and attacks. Child was born healthy. Mental development was appropriate with age. The first symptoms appeared at the age of 1 year while walking. Initially, a slight spastic lower paraparesis (walking on toes) was diagnosed. With time a spastic-dyskinetic walking appeared, worse to the left. From the age of 4, the regress of psychic functions began (The interest in fairy tales disappeared. The child became inattentive, ceased to maintain herself, memory decreased). Furthermore regress of speech began with the formation of extrapyramidal dysarthria and the poverty of speech. At the same time, the ambulation worsened, generalized epileptic seizures appeared. It is necessary to emphasize the fact that the family anamnesis is burdened on the father's line. Her father, grandfather, great-grandmother on the father's line had HD. Across pregnancy, testing of an amniotic fluid was conducted. 120 CAG repeats were detected. During the examination of the child the disruption of communication was determined (the girl performs some simple commands), dysphasia, extrapyramidal dysarthria (pronounces some obscure words, no phrasal language). In the neurological status there is pseudobulbar syndrome (hypersalivation), deviation of the tongue to the right. The gait is spastic-dystonic, worse to the left. Change in muscle tone by plastic type in arms and legs, more to the left; hyperkinesia in the fingers (athetosis), dystonia in the feet and feet clonus. On the MRI there was a moderately expressed diffuse decrease in the volume of parenchyma of both cerebellar hemispheres, the deepening and expansion of the cerebellar grooves, some thinning of the cerebellar stalks. Also there are no cerebellar tonsils, wide Magendie's foramen, and a moderately enlarged cisterna magna. It is interesting to note that the MRI of cerebral hemispheres, basal ganglia is without pathological changes. The electroencephalogram revealed generalized high-amplitude spike-wave epileptic activity during the entire recording. At the age of 4 years, the molecular genetic analysis was re-conducted; the number of CAG repeats was 130. For the treatment of epilepsy, the girl received antiepileptic drugs (valproates, lamotrigine) at maximum doses with minimal effect.

**Conclusions.** 1. Huntington's chorea is a severe autosomal dominant neurodegenerative disease with 100% mortality. 2. Genetic imprinting is characteristic for the disease. It is dependence of a form and severity of the disease onset from the parent source of the mutant chromosome. 3. At an early age and in youth the akinetic-rigid syndrome is prevalent. 4. Under 10 years of age, the disease may occur with epileptic seizures, so it is necessary to collect family anamnesis not only for epilepsy, but also for the progressive neurological and psychiatric diseases, including adults. 5. With the signs of progressing neurodegenerative disease in a child, it should not be rejected that there is the possibility of the Huntington's chorea diagnosis. Such families should be referred for medical genetic counseling.

**Key words:** children, neurodegeneration diseases, epilepsy, chorea.

### Хорея Гентингтона у дитини. Перше описання хвороби у дитини в Україні. Власне спостереження

*Т.І. Стеценко<sup>1</sup>, О.І. Савченко<sup>2</sup>, Н.З. Салан<sup>2</sup>, І.В. Головатюк<sup>2</sup>*<sup>1</sup>Національна медична академія післядипломної освіти імені П.Л. Шупика, м. Київ, Україна<sup>2</sup>Національна дитяча спеціалізована лікарня «ОХМАТДИТ» МОЗ України, м. Київ

Хвороба Гентингтона (ХГ, МКХ-10 — G-10, МКХ-11 — 8A01.10) — аутосомно-домінантне нейродегенеративне захворювання, яке характеризується руховими порушеннями (хорея у дорослих та акінетико-ригідний синдром у дітей), психічними розладами та деменцією з прогресуючим перебігом і летальністю 100%.

**Мета:** представити унікальний випадок діагностованого захворювання хореї Гентингтона у дитини віком 4 років у третьому поколінні в родині. Даний випадок описується в Україні вперше.

**Результати.** Наводимо власний досвід спостереження та лікування дівчинки 4 років 7 місяців, яка госпіталізована в НДСЛ «ОХМАТДИТ» зі скаргами на втрату мовних і психічних навичок, порушення ходи та наявність нападів. З 4-річного віку почався регрес психічних функцій (пропав інтерес до казок, стала неуважною, погіршилася пам'ять, перестала себе обслуговувати) і мовлення з формуванням екстрапірамідної дизартрії та збіднінням мовленнєвого запасу. В цей же час погіршилася хода, з'явилися генералізовані епілептичні напади. Необхідно акцентувати увагу тому те, що сімейний анамнез обтяжений по лінії батька — у батька, дідуся, прабабці по батьковій лінії хорея Гентингтона. При огляді у дитини було виявлено порушення комунікації, дисфазію, екстрапірамідну дизартрію, псевдобульбарний синдром. Хода спастико-дистонічна, гірше зліва. Зміна м'язового тону по пластичному типу в руках і ногах, більше зліва; гіперкінези в пальцях рук (атетоз), дистонія в стопах, клонуси стоп. На МРТ відмічалось помірно виражене дифузне зменшення об'єму паренхіми обох півкуль мозочка, заглиблення та розширення борозн мозочка, деяке стоншення мозочкових ніжок; також відсутні мигдалики мозочка, широкий отвір Мажанді та помірно збільшена в об'ємі велика цистерна. На електроенцефалограмі було виявлено генералізовану високоамплітудну пік-хвильову епілептичну активність під час всього запису. У віці 4 років був повторно проведений молекулярно-генетичний аналіз, кількість ЦАГ — повторів становила 130 та був підтверджений діагноз хвороби Гентингтона.

**Висновки.** 1. Для хвороби характерний генетичний імпринтинг — залежність форми і важкості проявів захворювання від батьківського джерела мутантної хромосоми. 2. У дитячому та юнацькому віці домінує акінетико-ригідний синдром. 3. У дитячому віці (до 10 років) хвороба може дебютувати епілептичними нападами, тому необхідно збирати сімейний анамнез не лише щодо епілепсії, але й на предмет прогресуючих неврологічних та психіатричних захворювань. В тому числі у дорослих. 4. При ознаках прогресуючого нейродегенеративного захворювання у дитини не слід відкидати можливість діагнозу хореї Гентингтона, потрібно скеровувати такі сім'ї на медико-генетичне консультування.

**Ключові слова:** діти, нейродегенеративні хвороби, епілепсія, хорея.

## Болезнь Гентингтона у ребенка. Первое описание заболевания у ребенка в Украине. Собственное наблюдение

Т.І. Стеценко<sup>1</sup>, О.І. Савченко<sup>2</sup>, Н.З. Салак<sup>2</sup>, І.В. Головатюк<sup>2</sup>

<sup>1</sup>Национальная медицинская академия последилового образования имени П.Л. Шупика, г. Киев, Украина

<sup>2</sup>Национальная детская специализированная больница «ОХМАТДЕТ» МЗ Украины, г. Киев

Болезнь Гентингтона (ХГ, МКХ-10 — G-10, МКХ-11 — 8A01.10) — аутосомно-доминантное нейродегенеративное заболевание, которое характеризуется двигательными нарушениями (хорея у взрослых и акинетико-ригидный синдром у детей), психическими расстройствами и деменцией с прогрессирующим течением и летальностью 100%.

**Цель:** представить уникальный случай диагностированного заболевания хореи Гентингтона у ребенка в возрасте 4 лет в третьем поколении в семье. В Украине данный случай описывается впервые.

**Результаты:** Представляем собственный опыт наблюдения и лечения девочки 4 лет 7 месяцев, которая поступила в НДСБ «ОХМАТДЕТ» с жалобами на потерю разговорных и психических навыков, нарушение походки и наличие приступов. С 4-летнего возраста начался регресс психических функций (пропал интерес к сказкам, стала невнимательной, ухудшилась память, перестала себе обслуживать) и речи с формированием экстрапирамидной дизартрии и обеднением словарного запаса. В это же время ухудшилась походка, появились генерализованные эпилептические приступы. Необходимо акцентировать внимание на том, что семейный анамнез отягощен по линии отца — у отца, деда, прабабушки по отцовской линии хореи Гентингтона. При осмотре у ребенка были выявлены нарушения коммуникации, дисфазия, экстрапирамидная дизартрия, псевдобульбарный синдром; походка — спастико-дистоническая, хуже слева; изменение мышечного тонуса по пластическому типу в руках и ногах, больше слева; гиперкинезы в пальцах рук (атетоз), дистония в стопах, клонусы стоп. На МРТ отмечались умеренно выраженные диффузное уменьшение объема паренхимы обоих полушарий мозжечка, углубленная и расширенная борозда мозжечка, некоторое уточнение мозжечковых ножек; также отсутствовали миндалины мозжечка, широкое отверстие Мажанди и умеренно увеличенная в объеме большая цистерна. На электроэнцефалограмме была выявлена генерализованная высокоамплитудная пик-волновая эпилептическая активность во время всей записи. В возрасте 4 лет был повторно проведен молекулярно-генетический анализ, количество ЦАГ-повторов составило 130 и был подтвержден диагноз болезни Гентингтона.

**Выводы.** 1. Для болезни характерен генетический импринтинг — зависимость формы и тяжести проявлений заболевания от отцовского источника мутантной хромосомы. 2. В детском и юношеском возрасте доминирует акинетико-ригидный синдром. 3. В детском возрасте (до 10 лет) болезнь может дебютировать эпилептическими приступами, поэтому необходимо собирать семейный анамнез не только по эпилепсии, но и относительно неврологических и психиатрических заболеваний, в том числе у взрослых. 4. При признаках прогрессирующего нейродегенеративного заболевания у ребенка не следует отбрасывать возможность диагноза хореи Гентингтона нужно направлять такие семьи на медико-генетическое консультирование.

**Ключевые слова:** дети, нейродегенеративные болезни, эпилепсия, хорея.

Huntington's disease (HD, ICD-10 — G-10, ICD-11 — 8A01.10) — is an autosomal dominant neurodegenerative disease characterized by motor disorders (chorea in adults and akinetic-rigid syndrome in children), mental disorders and dementia with progressive course and mortality of 100%.

The disease was described for the first time by the American physician George Huntington in 1872. The basis of the pathogenesis is an increase in the number of triplet repeats of cytosine-adenine-guanine (CAG) in the IT215 gene on the chromosomal segment 4p16.3, that encode huntingtin protein, the exact function of which remains unknown. In its first exon, the gene has a tandem sequence of CAG repeats, the number of which is normally from 6 to 20.

The essence of mutation in the Huntington's chorea is the expansion of intragenic tandem trinucleotide repeats, the number of which in patients is increased to 36–180. The prevalence rate of HD in the adult population is about 10: 10 000, while in Western Europe the rate ranges from 3 to 7 cases per 100 000, and in North America — from 5 to 10 per 100 000 [8,9]. Among the children's population there are no statistical data due to the rarity of cases. Onset of HD is usually observed at the age of 35–40 years. Approximately in 10% of cases the disease occurs prior to 20 years old [1]. The division into juvenile form

(onset at the age of 10–20 years) and the children's form (onset from 3 to 9 years) is generally accepted. The children's form is not more than 5% of all cases of HD and usually occurs in cases when the patients are the father and grandfather of the proband (the phenomenon of anticipation in the male line) [1, 9]. Over the last 5 years, 6 cases of Huntington's disease have been described in the literature with the onset prior to 20 years old.

All patients were males at the age of 4 to 17 years. They had a number of CAG repeats from 49 to 169, which correlated with the age of the onset and the severity of the disease — the greater the number of repeats, the earlier the disease began and had more severe course [3,5–7,10,11]. For all forms, a triad of signs is characteristic: motor disorders, mental disorders and progressive dementia. The disease begins with motor or mental disorders; signs of dementia develop as the pathology progresses.

A distinctive feature of the clinical picture of HD with the onset prior to 20 years is the beginning of disease with akinetic-rigid set of symptoms. There is slowness and constrained movements, a masked facies, shuffling gait. Dystonic muscular tone with tendency to increase by plastic type; tendon reflexes are not changed or slightly brisk. The static tremor is often characterized by a frequency of 4–5 per second. Often there are cerebellar symptoms: ataxia, kinetic tremor, nystagmus, asynergia, syllabic speech. At the onset of HD in

childhood hyperactivity and emotional lability are noted; negativism is increasing; there are difficulties in studying. In future there is an arrest of mental development with the subsequent loss of mental skills.

A separate issue for discussing HD with the onset prior to 10 years old is the frequent development of epilepsy [2]. Epileptic seizures are detected in 30–50% of patients with the onset of disease prior to 10 years old and only in 2% of patients in classical form [9]. Epilepsy occurs, on average, two years after the first symptoms appear: motor, cognitive or mental disorders. The following types of seizures are characteristic: myoclonic and myoclonic-astatic, atypical absences, generalized clonic-tonic seizures. On EEG characteristic epileptiform pathognomonic phenomena are not recorded. Spike/polyspike wave activity or long spike-wave discharges with the frequency of about 3 Hz with bifrontal predominance (EEG-pattern of atypical absences) are recorded and positive effect of photostimulation (Fig. 1–3).

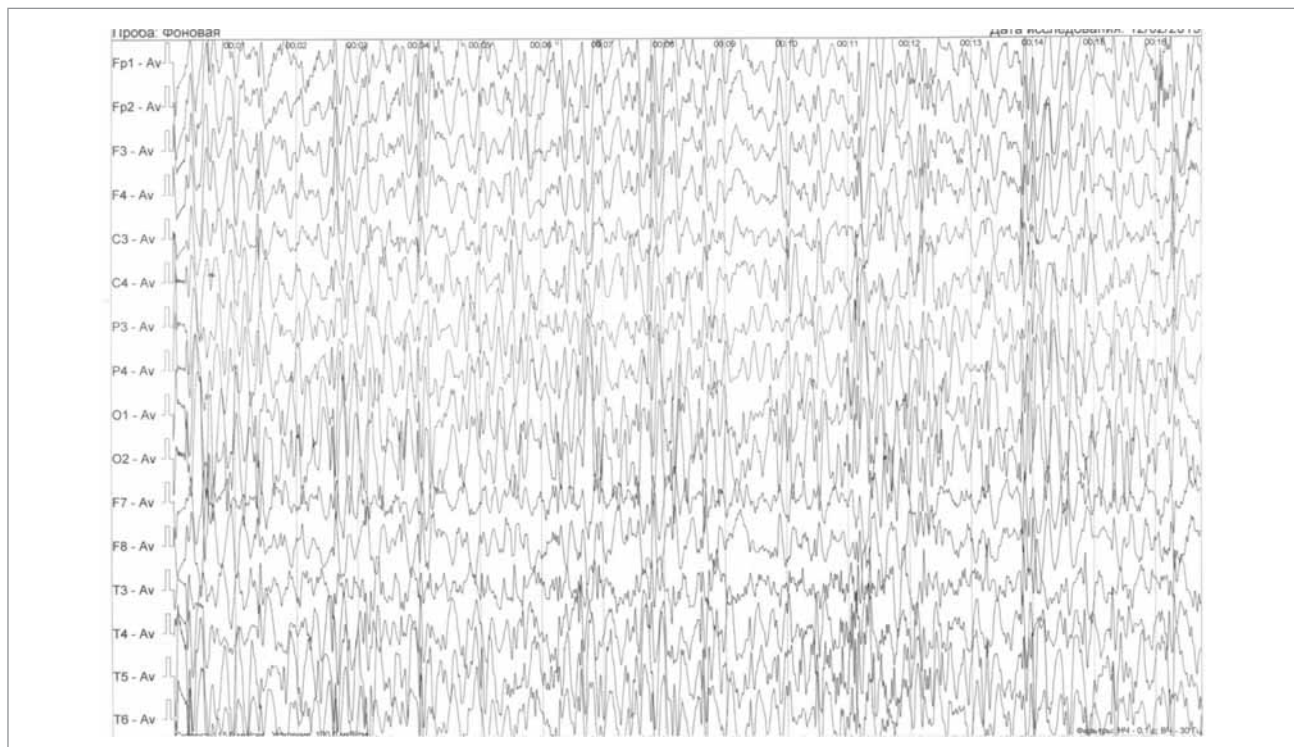
In neuroimaging, a typical picture is determined: on the brain MRI, the atrophy of the head of the caudate nucleus, striatum, cerebral cortex with ventriculomegaly in the form of «butterfly wings» is diagnosed (Fig. 4).

The exact diagnosis is established according to modern methods – the molecular genetic analysis with the determination of the number of CAG repeats.

Depending on the number of CAG repeats, there is a subsequent gradation of the possible development of a disease:

- $\leq 26$  repeats – normal alleles;
- 27–35 repeats – transitional alleles. The disease doesn't develop in an individual with such number of repeats, but there is a risk of transferring their allele with an abnormally increased number of repeats to their children. The risk of the disease developing is 6–10%;
- 36–39 repeats – alleles with variable penetrance;
- $\geq 40$  repeats – full penetrance. These alleles are associated with the development of the Huntington's chorea.

There is a direct correlation between the number of repeats and the degree of phenotypic manifestation of the disease and the inverse correlation with the age of the manifestation. For the Huntington's chorea, the phenomenon of anticipation is characteristic – increasing the severity of the disease and reducing the age at which it occurs in subsequent generations. The reason is the accumulation of CAG repeats when inherited. In this case, an increase in their number is observed more often with transferring of the mutant gene from the father. This phenomenon is called genetic imprinting. Huntington's Disease is differentiated with other neurodegenerative diseases that manifest with the seizure and akine-



**Fig.1.** EEG of patient. Spike/polyspike wave activity or long spike-wave discharges with the frequency of about 3 Hz with bifrontal predominance (EEG-pattern of atypical absences) (amplitude 100mkV/sm)

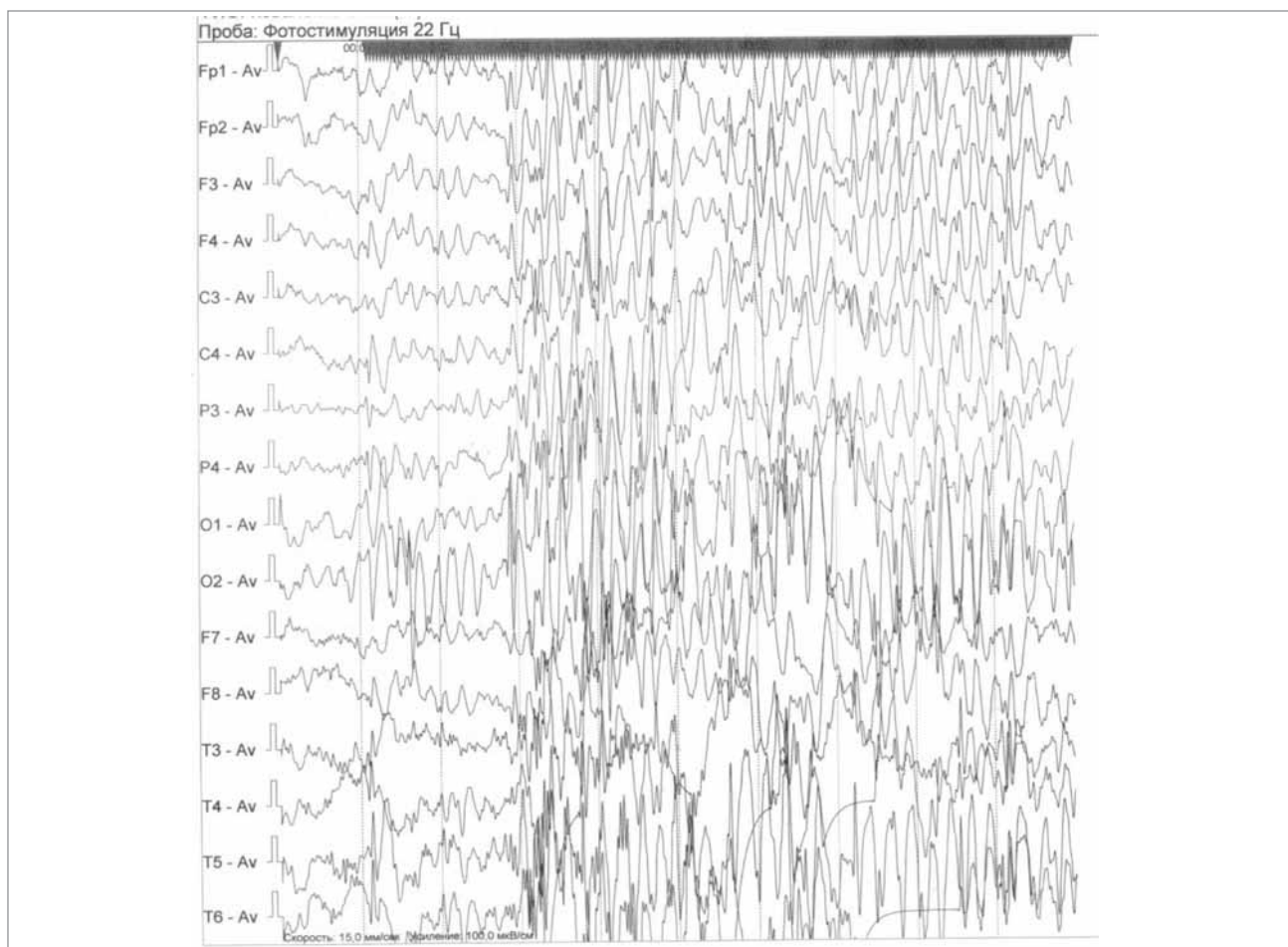


Fig. 2. EEG result of photostimulation (amplitude 100mkV/sm)

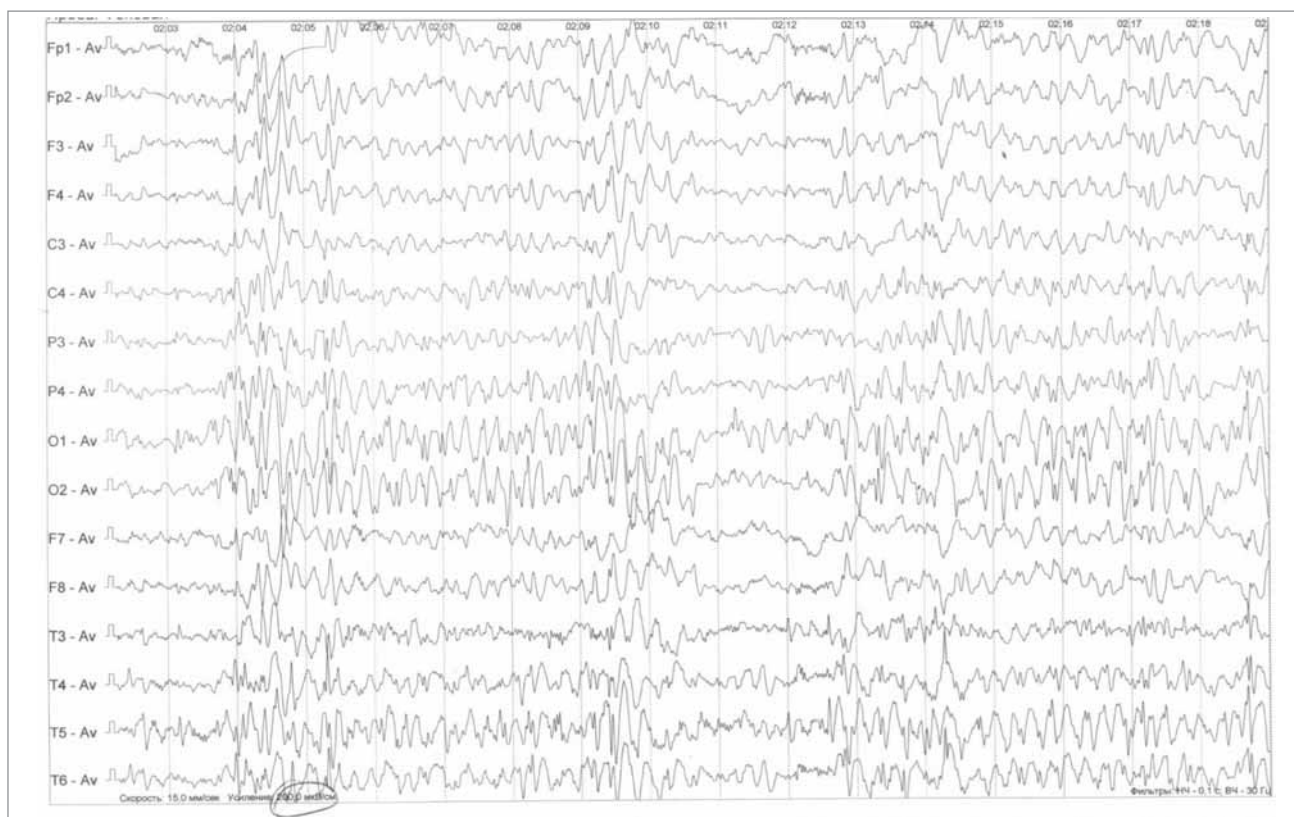
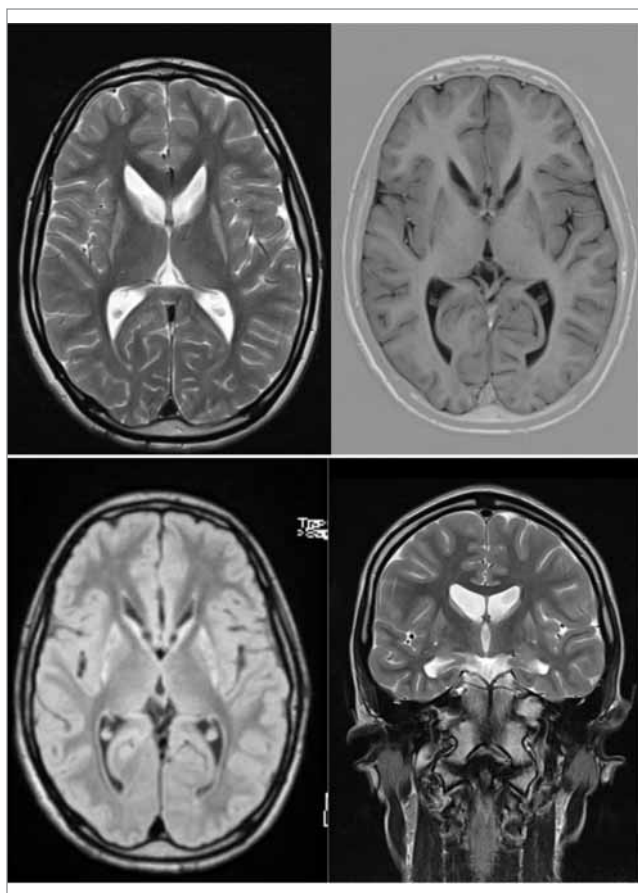


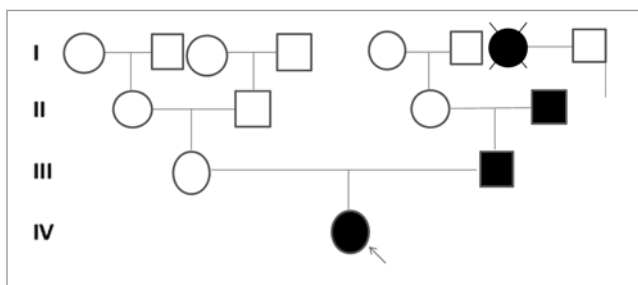
Fig. 3. EEG polyspike wave activity or long spike-wave discharges. (amplitude 200 mkV/sm)



**Fig. 4.** On the brain MRI, the atrophy of the head of the caudate nucleus, striatum, cerebral cortex with ventriculomegaly in the form of «butterfly wings» is diagnosed

tic-rigid syndrome (diseases with iron accumulation, neuronal ceroid lipofuscinosis).

HD therapy is exclusively symptomatic. Treatment is aimed primarily at reducing the manifestations of rigid syndrome in children, as well as mitigating mental disorders. Unfortunately, there is not enough literature on the management of epilepsy in children with HD, therefore, a recommendation is made for the use of antiepileptic drugs with a broad mechanism of action (valproates, lamotrigine, TPM, levetiracetam). The duration of the disease varies, but on average it is 15 years in the classical form, about 10 years in the juvenile form and 4–6 years in the children form. Mortality is 100% [7].



**Fig. 5.** Genealogical tree of patient

**Aim of research:** to present a unique case of Huntington's chorea diagnosed in a child at the age of 4 in the third generation in the family. This case is described for the first time in Ukraine.

The research was carried out in accordance with the principles of the Helsinki Declaration. The study protocol was approved by the Local Ethics Committee (LEC) of all participating institution.

The informed consent of the patient was obtained for conducting the studies.

### Results of research

We present our own experience of observation and treatment of a girl at the age of 4 years and 7 months who has been admitted to the NCSH «OKHMATDYT» with complaints about linguistic and psychic skills loss, ambulation disorder, and periodic falls from her standing height, episodes of urinary incontinence and attacks. From the anamnesis it is known that the child was born from the first pregnancy, which ran on the background of toxicosis. It was the 1st natural delivery at term of 40 weeks. The weight of a child was 3 kg, height – 53 cm. Mental development was appropriate with age. The first symptoms appeared at the age of 1 year while walking. The child walked on the toes with uncertainty. Due to these symptoms there were some courses of rehabilitation. Initially, a slight spastic lower paraparesis (walking on toes) was diagnosed. With time a spastic-dyskinetic walking appeared, worse to the left. From the age of 4, the regress of psychic functions began (The interest in fairy tales disappeared. The child became inattentive, ceased to maintain herself, memory decreased). Furthermore regress of speech began with the formation of extrapyramidal dysarthria and the poverty of speech. At the same time, the ambulation worsened, generalized epileptic seizures appeared.

It is necessary to emphasize the fact that the family anamnesis is burdened on the father's line. Her father, grandfather, great-grandmother on the father's line had HD (Fig. 5). Despite the fact that the father has 180 CAG repeats and HD manifests in the III generation, there are slight motor disorders and no mental changes in the clinical picture. Across pregnancy, testing of an amniotic fluid was conducted. 120 CAG repeats were detected, that means, the mother knew her daughter's diagnosis before her birth.

During the examination of the child the disruption of communication was determined (the girl performs some simple commands), dysphasia, extrapyramidal dysarthria (pronounces some obs-

cure words, no phrasal language). In the neurological status there is pseudobulbar syndrome (hypersalivation), deviation of the tongue to the right. The gait is spastic-dystonic, worse to the left. Change in muscle tone by plastic type in arms and legs, more to the left; hyperkinesia in the fingers (athetosis), dystonia in the feet and feet clonus. On the MRI there was a moderately expressed diffuse decrease in the volume of parenchyma of both cerebellar hemispheres, the deepening and expansion of the cerebellar grooves, some thinning of the cerebellar stalks. Also there are no cerebellar tonsils, wide Magendie's foramen, and a moderately enlarged cisterna magna. It is interesting to note that the MRI of cerebral hemispheres, basal ganglia is without pathological changes. The electroencephalogram revealed generalized high-amplitude spike-wave epileptic activity during the entire recording. At the age of 4 years, the molecular genetic analysis was re-conducted; the number of CAG repeats was 130.

As a result the diagnosis was established: Huntington's chorea, spastic tetraparesis, more on the left. Akinetic-rigid syndrome. Genetic epilepsy. For the treatment of epilepsy, the girl received

antiepileptic drugs (valproates, lamotrigine) at maximum doses with minimal effect.

### Conclusions

1. Huntington's chorea is a severe autosomal dominant neurodegenerative disease with 100% mortality.

2. Genetic imprinting is characteristic for the disease. It is dependence of a form and severity of the disease onset from the parent source of the mutant chromosome.

3. At an early age and in youth the akinetic-rigid syndrome is prevalent.

4. Under 10 years of age, the disease may occur with epileptic seizures, so it is necessary to collect family anamnesis not only for epilepsy, but also for the progressive neurological and psychiatric diseases, including adults.

5. With the signs of progressing neurodegenerative disease in a child, it should not be rejected that there is the possibility of the Huntington's chorea diagnosis. Such families should be referred for medical genetic counseling.

*No conflict of interest was declared by the authors.*

### REFERENCES/ЛІТЕРАТУРА

- Aicardi J, Bax M., Gillberg Ch. (2013). Diseases of the nervous system in children. 3th edition. Moscow. Binom: 383—386.
- Barcovich AJ, Raubaud Ch. (2012). Pediatric neuroimaging. 5th edition. Philadelphia. Lippincott: 383—386.
- Choudhary A, Minocha P, Sitaraman S. (2017). A case report of juvenile Huntington disease. Journal of Pediatric and Neonatal Individualized Medicine. 6(2): e060217.
- Fahn S. (2000). Huntington disease. In: Merrit's Neurology 10th edition. Eds.: L.P. Rowland. Lippincott, Philadelphia: 659—662.
- Kailash Chandra Patra, Mukund Sudhir Shirolkar. (2015). Childhood-onset (Juvenile) Huntington's disease: A rare case report. J Pediatr Neurosci. 10(3): 276—279.
- Kendrick LM, Hudgell D, Hellman A, Weaver MS. (2019). Attending to Total Pain in Juvenile Huntington Disease: A Case Report Informed by Narrative Review of the Literature. J Palliat Care. 5: 825859719835560.
- Latimer CS, Flanagan ME, Cimino PJ, Jayadev S, Davis M, Hoffer ZS, Montine TJ, Gonzalez-Cuyar LF, Bird TD, Keene CD. (2017) Neuropathological Comparison of Adult Onset and Juvenile Huntington's Disease with Cerebellar Atrophy: A Report of a Father and Son. J Huntingtons Dis. 6(4): 337—348.
- Lyon G, Kolodny EH, Pastores GM. (2006). Neurology of Hereditary Metabolic Diseases of Children. 3-d edition. NY: McGraw-Hill: 281—284.
- Mukhin KYu, Oysyachina ID, Sawin DA, Piliya SV, Petrukhin AS. (2010). Childhood onset form of Huntington's disease (clinical case). Russkiy zhurnal detskoy neurologii. 1(5): 35—42.
- Shi-Shuang Cui, Ru-Jing Ren, Ying Wang, Gang Wang, Sheng-Di Chen. (2017). Tics as an initial manifestation of juvenile Huntington's disease: case report and literature review. BMC Neurology. <https://doi.org/10.1186/s12883-017-0923-1>
- Weinmann ARO, Souza GA, Souza GA, Sandim GB, Giuliani LR. (2017). Case Report: Huntington's disease in four years old male. European journal of paediatric neurology. 2(1): 61—62.

### Відомості про авторів:

**Стеценко Тетяна Іванівна** — к.мед.н., доц. каф. дитячої неврології та медико-соціальної реабілітації НМАПО імені П.Л. Шупика.

Адреса: м. Київ, вул. Дорогожицька, 9; тел. (044) 412-10-68. <http://orcid.org/0000-0002-9490-3782>

**Савченко Олена Іванівна** — зав. неврологічним відділенням НДСЛ «ОХМАТДИТ». Адреса: м. Київ, вул. Чорновола, 28/1; тел. (044) 236-76-95. <http://orcid.org/0000-0002-3822-1963>

**Салан Наталія Зіновівна** — лікар-дитячий невролог неврологічного відділення НДСЛ «ОХМАТДИТ».

Адреса: м. Київ, вул. Чорновола, 28/1; тел. (044) 236-76-95. <http://orcid.org/0000-0002-5811-2262>

**Головатюк Ірина Володимирівна** — лікар-дитячий невролог неврологічного відділення НДСЛ «ОХМАТДИТ».

Адреса: м. Київ, вул. Чорновола, 28/1; тел. (044) 236-76-95. <http://orcid.org/0000-0002-4087-1957>

Стаття надійшла до редакції 18.02.2019 р., прийнята до друку 19.05.2019 р.